

Periorbital dermatitis: Causes, differential diagnoses and therapy

Alexandra Feser, Vera Mahler

Department of Dermatology, University Hospital of Erlangen, Friedrich-Alexander University, Erlangen-Nürnberg, Germany

JDDG; 2010 · 8:159–165

Submitted: 4.6.2009 | Accepted: 26.6.2009

Keywords

- periocular eczema
- periorbital dermatitis
- risk factors
- allergic contact dermatitis
- irritant contact dermatitis
- atopic dermatitis

Summary

Periorbital dermatitis is common and frequently difficult to treat. Patients with periorbital dermatitis often suffer severely because their disease is in such a visible location. Because of the variety of clinical appearance, the differential diagnostic considerations are often difficult. We examined the causes of periorbital dermatitis and compared the data of 88 patients from the Department of Dermatology, University Hospital Erlangen to those of the German IVDK (Information Network of the Departments of Dermatology). Between 1999 and 2004, predominant causes of periorbital dermatitis were allergic contact dermatitis (Erlangen 44 %, IVDK 32 %), atopic eczema (Erlangen 25 %, IVDK 14 %), airborne contact dermatitis (Erlangen 10 %, IVDK 2 %) and irritant contact dermatitis (Erlangen 9 %, IVDK 8 %). Less frequent causes for secondary eczematous periocular skin lesions were periorbital rosacea, allergic conjunctivitis or psoriasis vulgaris. Female gender, atopic skin diathesis and age of 40 years and older were identified as risk factors for periocular dermatitis. Common elicitors of periorbital allergic contact dermatitis were leave-on cosmetic products (face cream, eye shadow) and eye drops with the usual allergens being fragrances, preservatives and drugs. Exact identification of relevant contact allergens and allergen elimination are essential for successful treatment. Calcineurin inhibitors are the first-line therapy for facial atopic eczema. They may be also effective in periocular eczematous lesions of other origins although they are not approved for such use.

Introduction

Periorbital dermatitis is a commonly occurring dermatological disorder that is often resistant to therapy. A recent study at the Department of Dermatology, University Hospital of Erlangen (Germany) and the Information Network of Departments of Dermatology (Informationsverband Dermatologischer Kliniken, IVDK) suggests that the incidence of periorbital dermatitis is 4.8 % and 3.9 % respectively [1]. There are no recent epidemiological data on the prevalence

in the general population in the literature.

Because of the visible involvement of the face, most patients with periorbital dermatitis are highly distressed [2]. The disorder is usually persistent and patients often undergo repeated therapies with topical corticosteroids, which tend to fail to achieve lasting improvement or resolution of the dermatitis and can also involve steroid-induced side effects (skin atrophy, telangiectasias, rebound phenomenon) [3].

Periocular dermatitis may be caused by allergic or irritant contact dermatitis, protein contact dermatitis, secondary eczematous periocular rosacea and further skin disorders of another origin. Pathogenesis can also be multifactorial.

Epidemiology of periocular dermatitis

In 1989 Nethercott and colleagues reported that in 79 patients with periocular dermatitis (total sample: n = 1 091) there was a clear preponderance of

women at 89 %, with a slightly higher average age of 41.4 years compared with the total sample (40.5 years) [4]. These results were confirmed by subsequent epidemiological studies on periocular dermatitis: In a study conducted from 1994 to 1998, Cooper and Shaw reported a significantly higher prevalence of periocular dermatitis among women, at 84.9 % of 232 patients (total sample: n = 311 of a patch tests clinic) [5]. In a study from 1990–1994, Ockenfels and colleagues reported a predominance of women of 81 % among 609 patients with periorbital dermatitis (total sample: n = 30690) [6]. Herbst and colleagues found that women made up 80.3 % of 1,641 patients with periocular dermatitis out of a total of 49,256 patients tested between 1995–1999 [7].

Epidemiological studies on patients with periocular dermatitis from 1999–2004 have confirmed that female sex (Erlangen 73.9 %, IVDK 78.8 %) is a risk factor (Table 1), although for the first time of a proportion below 80 % [1]. The high prevalence of women among patients with periorbital dermatitis has been attributed to the more frequent use of cosmetic products [5].

There is an increased frequency of atopic skin diathesis in patients with periocular dermatitis (1995–1999) (28.2 % vs. 16.2 % of total sample) [7]. Atopic skin diathesis was recently confirmed as a risk factor for the development of periocular dermatitis (1999–2004): in one study, 44.3 % of patients with periocular dermatitis had a history of atopic dermatitis compared with 29.2 % in the entire sample of all patients (n = 1827) who had undergone a patch test from 1999–2004 at the Department of Dermatology of the University Hospital of Erlangen (Table 1) [1]. Among patients with periocular dermatitis in the IVDK sample (1999–2004), a higher proportion had a history of atopic eczema also (22.9 % periocular dermatitis vs. 16.2 % of total sample) [1].

An average atopy score [8] of 10.5 points (assessment: atopic skin diathesis) has been reported in patients with periorbital dermatitis [1]. Patients with periocular atopic dermatitis had an average over 12 points (assessment: atopic skin diathesis), patients with periorbital allergic contact dermatitis had an average of 9.7 points (assessment: atopic skin diathesis), patients with irritant contact

Table 1: The MOAHLFA-index is an instrument to characterize different test populations for concise interpretation of patch test study results. The MOAHLFA-index of all patch-tested patients in Erlangen and in the IVDK-collective (excluding Erlangen) is displayed and compared with the MOAHLFA-index of patients with periorbital dermatitis in Erlangen and in the IVDK-collective (excluding Erlangen) between 1999 and 2004.

		Total		Periocular	
		Erlangen (n = 1827)	IVDK (n = 52580)	Erlangen (n = 88)	IVDK (n = 2035)
M	Male	40.5 %	38.0 %	26.1 %	21.2 %
O	Occupational	14.7 %	14.3 %	5.7 %	2.7 %
A	Atopic dermatitis	29.2 %	16.2 %	44.3 %	22.9 %
H	Hand dermatitis	27.4 %	26.8 %	0 %	0 %
L	Leg dermatitis	6.1 %	11.3 %	0 %	0 %
F	Facial dermatitis	13.5 %	14.0 %	100 %	100 %
A	Age ≥ 40	61.1 %	65.7 %	71.6 %	70.3 %

dermatitis had an average 4.4 points (assessment: no atopic skin diathesis). The periocular region is a predilection site for atopic dermatitis and can be irritated by aeroallergens (e.g., pollen, house dust mites) [9]. Abnormal skin barrier function can promote the development of sensitization [10, 11].

Age (≥40 years) has also been identified as a risk factor in periocular dermatitis [1]. In the Erlangen and IVDK samples, more than 70 % of patients with periorbital dermatitis were over 40 years of age (Table 1), which is a higher average age than in the total sample. In the Erlangen sample, there was an increased frequency of periocular dermatitis in patients aged 50 years and older (Figure 1) [1]. Another study found that the age of patients with allergic periocular dermatitis was higher than in patients with “non-allergic periocular dermatitis” [7]. This is attributed in part to the more common use of ophthalmologic medications because of a higher prevalence of ophthalmologic disease (e.g., glaucoma) in older patients [12].

Differential diagnosis and clinical examination

The clinical appearance of various differential diagnoses in periocular eczema is sometimes uncharacteristic and is not diagnostically conclusive (Figure 2a–g).

The most commonly reported cause of periocular dermatitis is contact allergy at 54 % (44 % due to direct contact; 10.2 % due to airborne contact dermatitis) [1]. Other causes of eczematoid periocular skin lesions include atopic dermatitis (25 %), irritant contact dermatitis (9.1 %), and secondary eczematous skin lesions in periorbital rosacea (4.5 %), periorbital psoriasis vulgaris, and allergic conjunctivitis at 2.1 % each [1].

In a retrospective study conducted from 1997–2003 at the University of Arkansas (USA) on 203 patients with periocular dermatitis, a clinically manifest allergic contact dermatitis was reported in 74 % of patients (n = 151), protein contact dermatitis in 23 %, and in less than 1 % irritant contact dermatitis was identified as the sole trigger [13]. Differences in the frequencies of the various causes of periocular dermatitis are due partly to different exposures and partly to differences in selection criteria of the studies.

Allergic contact dermatitis

Periocular dermatitis is most often caused by an allergic reaction. In one study, an allergic or airborne allergic contact dermatitis was identified as the responsible trigger in 54 % of patients; a non-allergic cause was found in the remaining 46 % [1].

When diagnosing allergic contact dermatitis, a specific medical history should

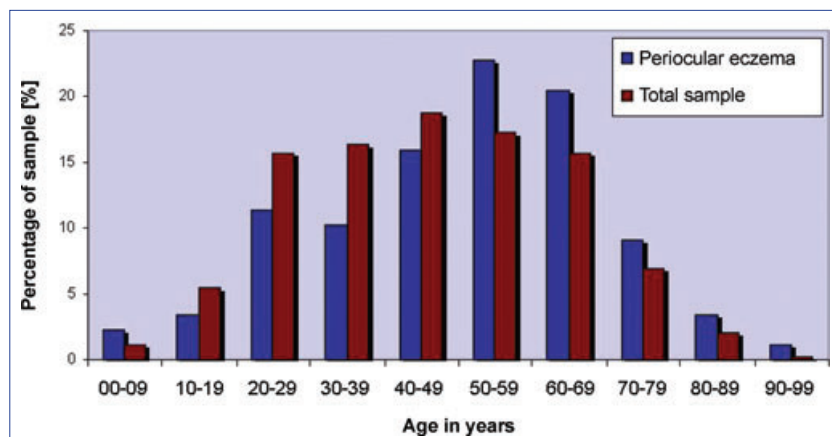


Figure 1: Age distribution of patients with periorbital dermatitis (n = 88) compared with all patch-tested patients (n = 1 827) in Erlangen 1999–2004: the normal curve of distribution is shifted to an age \geq 50 years.

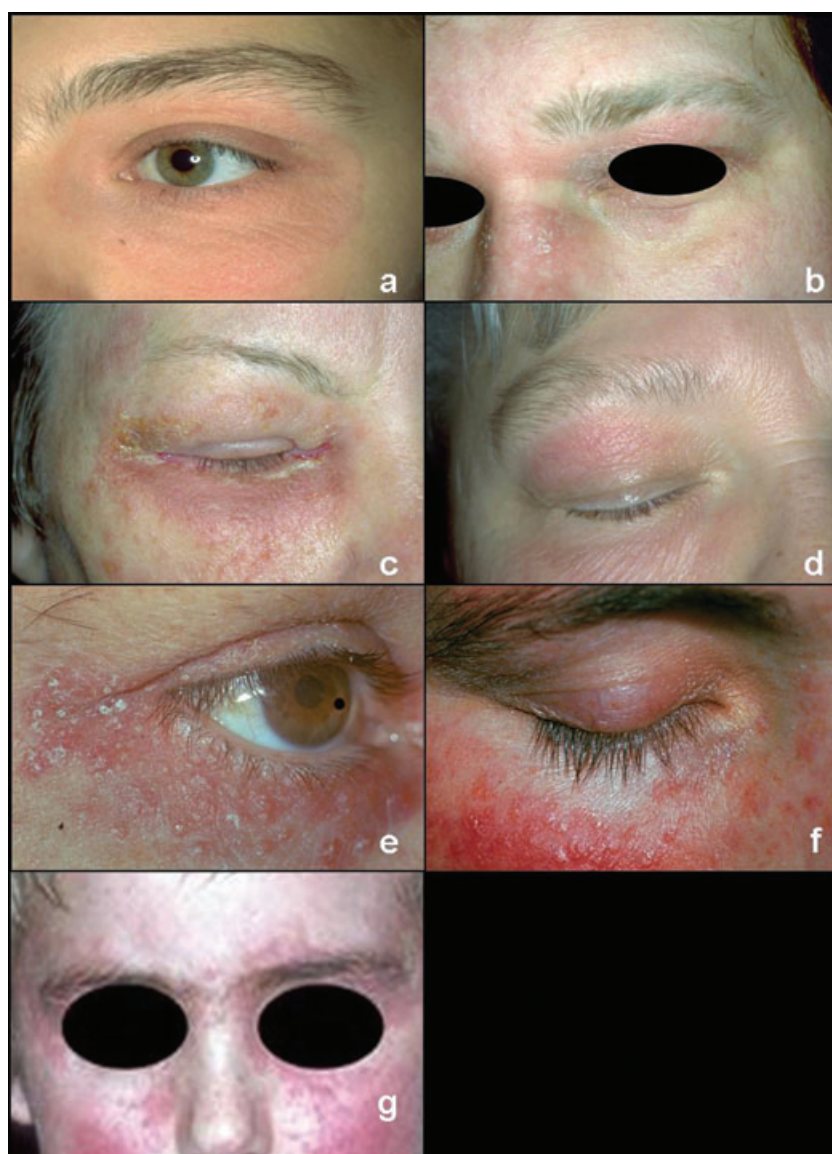

Figure 2: Periorbital atopic eczema (a, b), periorbital allergic contact dermatitis (c, d), periorbital rosacea (e, f), periorbital psoriasis (g).

be taken and appropriate patch tests should be performed. The reader is referred to the guidelines of the German Society of Dermatology on “Contact Dermatitis” [14] and “Performing a patch test with contact allergens” [15]. Type IV hypersensitivity to nickel (II) sulfate is the most prevalent sensitization in the general population and is also commonly associated with periorbital dermatitis, regardless of whether it is relevant [15] to the dermatitis in question (Valsecchi et al.: 52 % periocular *versus* 25.5 % of total sample; Cooper & Shaw: 17.2 % periocular *versus* 15.9 % of total sample; Nethercott et al.: 13.5 % periocular *versus* 10.2 % total sample) [4, 5, 16]. At least one large study (n = 49,256) has found, however, that positive patch tests to nickel (II) sulfate were no more common in patients with allergic periorbital dermatitis than among patients with non-allergic periorbital dermatitis [7]. Although nickel (II) sulfate was the most commonly associated type IV allergy (19.5 %), it was only rarely (< 1 %) believed to be a clinically relevant cause of periocular dermatitis in a case-related assessment of relevance [1].

Nickel has been identified in cosmetic products used around the eyes such as mascara [17], make-up base [18], eye shadow [19], contact lens solution [20], and Kajal pencils [21]. Because the nickel is inadvertently incorporated during the manufacturing process, it is not listed as an ingredient in such products [13].

In a sample of patients studied from 1999–2004, fragrance mix and balsam of Peru were identified in 19 % and 10 % as the relevant contact allergens in triggering periocular dermatitis [1]. The relevance of fragrances in triggering periocular dermatitis varies depending on exposure and period in time. Cooper and Shaw reported a fragrance allergy in 6 % of patients with eyelid dermatitis (vs. 7.4 % in the total sample) [5]. In 1992 Valsecchi and colleagues reported fragrance allergies as the cause of periocular dermatitis in 8 % of patients (vs. 4.56 % in non-periocular dermatitis) [16]. Balsam of Peru is a mixture of natural ingredients consisting of more than 200 components, many of which are used in the fragrance and aroma industries [22]. The suitability of using balsam of Peru as a marker for fragrance allergy has been controversially discussed [22]. The

IVDK data showed an association between the presence of an allergy to balsam of Peru allergy and contact allergy to the patient's own personal products containing fragrance. Perfumes and cosmetic products now use extracts and distillates of balsam of Peru, which animal studies have shown to be less sensitizing than balsam of Peru itself [23]. Case studies have occasionally reported an association between oral administration of balsam of Peru (e.g., chocolate, marzipan, colas) and persistent allergic contact dermatitis [24]. Balsam of Peru is no longer used as an additive in medications (Red List 2009).

The preservatives thimerosal (10%), phenylmercuric acetate (8%) and the topical antibiotic neomycin sulfate (8%) were shown in a study from 1999–2004 to be relevant triggers of periocular dermatitis [1]. Thimerosal was formerly used as a preservative in medications such as eye drops, ointments used around the eyes, nasal sprays, injection solutions, vaccines, in cosmetic products, make-up base, eye make-up remover, and in contact lens solutions for cleansing and storage. As of 2008, thimerosal was included as an additive in 5 different medications (2 types of eye drops and 3 vaccines), and by 2009 it was in 4 different medications (1 eye drops and 3 vaccines) (Red List 2008, 2009). Thimerosal is now only rarely found in contact lens solutions and cosmetic products. Due to decreased exposure, thimerosal is presumably less likely to be a current triggering factor in clinically apparent periocular dermatitis.

In one study, in 31% of patients with periocular allergic or airborne contact dermatitis, the patients' personal products (face cream 20%, eye shadow 20%, ophthalmologic medications 20%, nail polish 13%, make-up 13%, mascara 7%, glue 7%) were identified as the relevant contact allergen source [1] (Figure 3). In 12.5% of patients with allergic or airborne allergic contact dermatitis, the triggers could only be diagnosed by conducting tests using the patients' own personal products, and not by patch testing of commercial selected series based on the patient's medical history. Possible contact allergens include preservatives and fragrances (including those which must be listed as well as those which are exempt) [25]. If patch testing with the patient's own personal

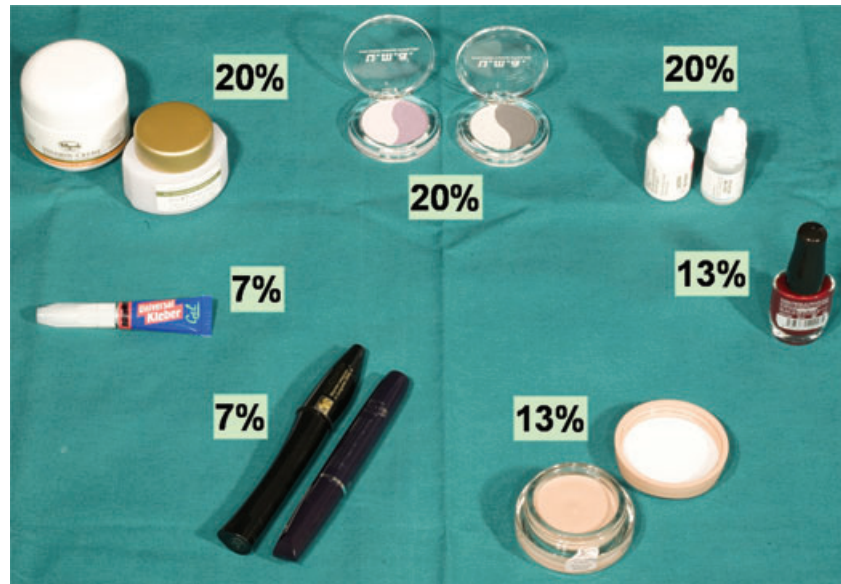

Figure 3: Hit list of consumers' products, which were elicitors for periorbital allergic contact dermatitis or airborne dermatitis (Department of Dermatology, University Hospital Erlangen 1999–2004): facial cream, eye shadow, ophthalmologic medications, nail polish, make-up, mascara, glue.

products is positive, individual substances should be tested; this requires written communication between the treating dermatologist and the manufacturer directly (which may be complicated by company confidentiality policy) or with the involvement of the Information and Documentation Center for Contact Allergy (Informations- und Dokumentationsstelle für Kontaktallergien, IDOK) [26] of the IVDK.

If the manufacturer does provide individual substances, the procedure is usually blinded. To determine scientifically sound, suitable patch test dilutions [27], the IDOK offers its support as an independent entity to manufacturers of cosmetics and body care products who provide the IDOK with complete and confidential information (which is not made available to the public) on the preparation in question. After blind testing of the substances, the treating dermatologist reports the results to IDOK. This procedure also helps improve product safety by standardized documentation and assessment.

Other potential triggers of airborne contact dermatitis include air fresheners and preservatives (e.g., chloromethylisothiazolinone in dispersion paints), nail polish (toluene sulfonamide-formaldehyde resin) and glues [1, 13, 28] (Figure 3). Numerous other causes of airborne contact dermatitis (e.g., plants, wood and natural resin, synthetic materials, metals,

pharmaceutical products, pesticides, and others) have also been reported in case studies [28].

Atopic dermatitis

In patients with periocular atopic dermatitis, it is helpful to collect information about minor signs of atopic skin diathesis (e.g., with the Erlangen Atopy Score [8]) to support the diagnosis. It is wise to rule out an additional sensitization to topical agents and exogenous triggers (e.g., through contact with proteins such as house dust mite allergens).

Protein contact dermatitis

Protein contact dermatitis (= IgE-mediated contact dermatitis) is an allergic skin reaction induced by plant or animal proteins. The reaction occurs with a delay after contact with the responsible protein. The clinical appearance is chronic dermatitis, the pathogenesis of which is attributed to IgE-mediated activation and allergen presentation of Langerhans cells and infiltration by T lymphocytes [29, 30]. Prior atopic or irritant damage of the skin barrier appears to be a relevant factor in the manifestation of protein contact dermatitis [30]. In patients with atopic dermatitis, protein contact sensitization has mostly been shown to plant or animal proteins (pollen, house dust mites, animal hair, foodstuffs, latex); it may occur after contact with the sensitive periocular region

[30]. Depending on the source of the allergen, diagnosis of IgE-mediated contact dermatitis includes avoidance of the allergen, an atopy patch test, patch testing, skin prick testing with native materials, and measurement of specific serum IgE [9, 30, 31]. The specificity of an atopy patch test can be higher, at 64–92 %, depending on the tested (aero) allergens than skin prick testing and serum IgE measurements (33–71 %), while sensitivity is lower [32]. Scratch chamber methods (patch test on a scratch test) are sometimes used (e.g., with native foods), but are not well standardized. In a sample of patients with periorbital dermatitis who participated in a study from 1999–2004, protein contact dermatitis (as a main diagnosis) played only a minor role [1]. Nineteen patients (48.7 %) out of 39 patients with a positive atopy patch test to house dust mites (out of $n = 150$ patients who underwent atopy patch testing) had eczematous skin lesions on the face or neck. In these patients, protein contact dermatitis was a secondary diagnosis along with pre-existing atopic dermatitis ($n = 14$) or allergic contact dermatitis ($n = 5$).

Irritant contact dermatitis

Irritant contact dermatitis is much less common at periorbital sites than on the hands where various (especially occupational) irritant exposures are possible [1, 33]. Dust, fumes, and mechanical factors can have an irritating effect on facial skin and should be considered as potential triggers in patients with periorbital dermatitis. A history of exposures and avoidance of allergens as well as the exclusion of allergic and atopic co-factors can aid diagnosis.

Periocular rosacea

The presence of multiple erythematous papules may be a sign of periocular rosacea. The diagnosis may be aided by the presence of pustules and telangiectasias around the mouth and/or eyes, although they are not always present. Patients often report a burning and stinging sensation [34]. Since rosacea can coexist with contact allergy, performing a patch test in patients with severe erythema and scaling may be wise to rule out an additional contact allergy [35]. In one study type IV hypersensitivity to propolis was shown to be significantly more common in patients with

rosacea compared with the total sample [35]. The same was shown in another study on type IV sensitivity to gentamicin sulfate, a result which is attributed to the increased use of topical antibiotics in rosacea patients [36].

Other differential diagnoses

Rare triggers of periocular dermatitis are secondarily eczematous skin disorders of other origins such as eczematous periorbital psoriasis vulgaris and conjunctivitis allergica (Erlangen study: 2.1 % each), drug intolerance (IVDK 1.8 %), and seborrheic dermatitis (IVDK 1999–2004: 0.9 %) [1]. Predilection sites for seborrheic dermatitis on the face are the nasolabial folds and the forehead, including the eyebrow region (T zone). The major pathophysiologic causes are thought to be excessive sebum production as well as abnormal colonization with *Malassezia* yeasts and the subsequent inflammatory reaction [37]. Periocular involvement is rare. Photoallergic and phototoxic triggers are rare and were not identified in the IDVK sample [1].

Therapy

If a contact allergy has been established as the cause of periorbital dermatitis, the treatment of choice is to avoid the allergen. The patient should be given concise information on the relevant contact allergens and should be given a formal documentation (in Germany an “allergy passport” is issued) listing the respective type IV allergens (possibly with additional information concerning potential sources) [15, 38]. It is also important to provide information on the International Nomenclature of Cosmetic Ingredients (INCI) declaration, which is used for listing cosmetics ingredients given that the abbreviations sometimes differ from those commonly used for contact allergens (e.g., oak moss absolute = *Evernia prunastri* extract [INCI], tree moss = *Evernia furfuracea* extract [INCI], Lyral® = hydroxyisohexyl-3-cyclohexene carboxaldehyde [INCI], dibromdicyanobutane = methyl-dibromoglutaronitrile [INCI]). The International Nomenclature of Cosmetic Ingredients was introduced on 1 January 1997 as a European regulation (96/335/EG) aimed at creating a standardized nomenclature for ingredients in cosmetic products [39, 40].

Symptoms may be treated with calcineurin inhibitors, the treatment of choice in atopic dermatitis affecting the periocular region [41]. Calcineurin inhibitors do not have any atrophogenic properties [3]. Numerous studies have demonstrated their efficacy in atopic dermatitis [42]. A recent systematic review recently provided evidence-based confirmation of the safety of topical calcineurin inhibitors in the treatment of atopic dermatitis involving the face [43]. The 2007 Cochrane review “topical pimecrolimus for eczema” including 31 studies ($n = 8\,019$ patients) showed that pimecrolimus was superior in short-term (≤ 6 weeks) and long-term studies (≥ 6 months) for the treatment of atopic dermatitis in reducing eczematous skin lesions ($n = 9$ long-term studies, $n = 3\,091$ patients, RR 1.47, 95 %, confidence interval of 1.32 to 1.64 after 6 months) and improving quality of life compared with vehicle [44]. Pimecrolimus was significantly less effective, however, than moderately or highly potent topical corticosteroids (triamcinolone acetonide 0.1 %, betamethasone valerate 0.1 %) or 0.1 % tacrolimus [44].

The only approved indication for calcineurin inhibitors is treatment of atopic dermatitis. Nevertheless, a number of placebo-controlled and open studies have shown the effectiveness of topical calcineurin inhibitors in the treatment of periorbital contact dermatitis, irritant contact dermatitis, seborrheic dermatitis, rosacea, facial, and intertriginous psoriasis vulgaris [37, 45–48]. The use in allergic contact dermatitis, seborrheic dermatitis, protein contact dermatitis, eczematous psoriasis vulgaris, rosacea, and other diagnoses is off-label (and thus involves potential liability issues and possible insurance claims). For off-label use, the patient must be thoroughly informed, and, if necessary, written consent should be obtained.

Animal studies have shown increased UV-induced carcinogenesis after topical application of calcineurin inhibitors; this has not been confirmed in humans however, protective measures against exposure to sunlight in accordance with the pertinent guidelines are recommended [49].

If calcineurin inhibitor therapy fails to achieve a significant effect, short-term use of newer topical corticosteroids with a good therapeutic index (TIX; the ratio

between objectively measured desired effects [anti-eczema effect, vasoconstriction] and undesirable effects [skin atrophy, adrenal cortex suppression, allergenic potential]) [50]. The topical corticosteroids methylprednisolone aceponate (substance class II, Advantan®) and prednicarbate (substance class II, Dermatop®), mometasone furoate (substance class III, Ecural®) for example have a TIX of 2.0 and thus a good efficacy/side effect profile [50]. Corticosteroids are not suitable for long-term therapy of periorbital dermatitis, and patients should be informed of this.

Experience has also shown positive effects of using facial masks with soft zinc paste (Pasta zinc mollis sine lanolin German Pharmacopoeia (DAB) [New German Formulary 11.21])/Unguentum leniens (DAB 10) (1: 1) and astringent black tea dressings.

Conclusion

Risk factors for periorbital dermatitis include female sex, age ≥ 40 years, and atopic skin diathesis. The most common cause is allergic contact dermatitis. Other common causes and differentials are periocular atopic dermatitis, periocular airborne contact dermatitis, irritant contact dermatitis, and periocular rosacea. Rare triggers include seborrheic dermatitis, secondarily eczematous conjunctivitis allergica, and periorbital psoriasis vulgaris. Diagnosis of allergic periocular dermatitis should be done with patch tests using commercial test series as well the patient's own personal care products – more than 10 % of cases of allergic contact dermatitis involving the periorbital region can only be diagnosed by patch testing of patients' own products, not by commercial series. Relevant test series in Germany for the diagnosis of periocular dermatitis, based on the patient's medical history, include the German Contact Dermatitis Group (DKG) standard, DKG topical agent ingredients, DKG preservatives, DKG ophthalmologic agents, and DKG medications. The treatment of choice in periorbital atopic dermatitis are calcineurin inhibitors (tacrolimus and pimecrolimus) [41] which may also be effective in the treatment of periocular dermatitis of causes other than those approved for prescription use. <<<

Conflict of interest

None.

Correspondence to



Priv.-Doz. Dr. med. Vera Mahler
Hautklinik Universitätsklinikum Erlangen
Hartmannstraße 14
D-91052 Erlangen
Tel.: +49-9131-853-3161
Fax: +49-9131-853-2724
E-mail: vera.mahler@uk-erlangen.de

References

- 1 Feser A, Plaza T, Vogelgsang L, Mahler V. Periorbital dermatitis – a recalcitrant disease: Causes and differential diagnoses. *Br J Dermatol* 2008; 159: 858–63.
- 2 Davies E, Patel C, Salek MS, Finlay AY. Does ad hoc quality-of-life discussion in inflammatory skin disease consultations reflect standardized patient-reported outcomes? *Clin Exp Dermatol* 2008; 33: 16–21.
- 3 Murrell DF, Calvieri S, Ortonne JP, Ho VC, Weise-Riccardi S, Barbier N, Paul CF. A randomized controlled trial of pimecrolimus cream 1 % in adolescents and adults with head and neck atopic dermatitis and intolerant of, or dependent on, topical corticosteroids. *Br J Dermatol* 2007; 157: 954–9.
- 4 Nethercott JR, Nield G, Holness DL. A review of 79 cases of eyelid dermatitis. *J Am Acad Dermatol* 1989; 21: 223–30.
- 5 Cooper SM, Shaw S. Eyelid dermatitis: an evaluation of 232 patch test patients over 5 years. *Contact Dermatitis* 2000; 42: 291–3.
- 6 Ockenfels HM, Seemann U, Goos M. Contact allergy in patients with periorbital eczema: an analysis of allergens. Data recorded by the Information Network of Departments of Dermatology. *Dermatology* 1997; 195: 119–24.
- 7 Herbst RA, Uter W, Pirker C, Geier J, Frosch PJ. Allergic and non-allergic periorbital dermatitis: patch test results of the Information Network of the Departments of Dermatology during a 5-year period. *Contact Dermatitis* 2004; 51: 13–9.
- 8 Diepgen TL, Fartasch M, Hornstein OP. Kriterien zur Beurteilung der atopischen Hautdiathese. *Dermatologie Beruf Umwelt* 1991; 39: 79–83.
- 9 Czarnecka-Operacz M, Bator-Wegner M, Silny W. Atopy patch test reaction to airborne allergens in the diagnosis of atopic dermatitis. *Acta Dermatovenerol Croat* 2005; 13: 3–16.
- 10 Vickery BP. Skin barrier function in atopic dermatitis. *Curr Opin Pediatr* 2007; 19: 89–93.
- 11 McLean WH, Hull PR. Breach delivery: increased solute uptake points to a defective skin barrier in atopic dermatitis. *J Invest Dermatol* 2007; 127: 8–10.
- 12 Rein DB, Zhang P, Wirth KE, Lee PP, Hoerger TJ, McCall N, Klein R, Tielsch JM, Vijan S, Saaddine J. The economic burden of major adult visual disorders in the United States. *Arch Ophthalmol* 2006; 124: 1754–60.
- 13 Guin JD. Eyelid dermatitis: experience in 203 cases. *J Am Acad Dermatol* 2002; 47: 755–65.
- 14 Brasch J, Becker D, Aberer W, Bircher A, Kränke B, Denzer-Fürst S, Schnuch A. AWMF-Leitlinie: Kontaktekzem. *J Dtsch Dermatol Ges* 2007; 5: 943–52.
- 15 Schnuch A, Aberer W, Agathos M, Becker D, Brasch J, Elsner P, Frosch PJ, Fuchs T, Geier J, Hillen U, Löffler H, Mahler V, Richter G, Szliska C. AWMF-Leitlinie: Durchführung des Epikutantests mit Kontakt-Allergenen. *J Dtsch Dermatol Ges* 2008; 6: 770–5.
- 16 Valsecchi R, Imberti G, Martino D, Cainelli T. Eyelid dermatitis: an evaluation of 150 patients. *Contact Dermatitis* 1992; 27: 143–7.
- 17 Brandrup F. Nickel eyelid dermatitis from an eyelash curler. *Contact Dermatitis* 1991; 25: 77.
- 18 Karlberg AT, Liden C, Ehrin E. Colophony in mascara as a cause of eyelid dermatitis. Chemical analyses and patch testing. *Acta Derm Venereol* 1991; 71: 445–7.
- 19 Van Ketel WG, Liem DH. Eyelid dermatitis from nickel contaminated cosmetics. *Contact Dermatitis* 1981; 7: 217.
- 20 Vilaplana J, Romaguera C, Grimalt F. Contact dermatitis from nickel and cobalt in a contact lens cleaning solution. *Contact Dermatitis* 1991; 24: 232–3.
- 21 Zemba C, Romaguera C, Vilaplana J. Allergic contact dermatitis from nickel in an eye pencil. *Contact Dermatitis* 1992; 27: 116.

- 22 Johansen JD, Andersen TF, Veien N, Avnstorp C, Andersen KE, Menné T. Patch testing with markers of fragrance contact allergy. *Acta Derm Venereol* 1997; 77: 149–53.
- 23 Api MA. Only Peru Balsam extracts or distillates are used in perfumery. *Contact Dermatitis* 2006; 54: 179.
- 24 Hausen BM. Rauchen, Süßigkeiten, Perubalsam – ein Circulus vitiosus? *Akt Dermatol* 2001; 27: 136–43.
- 25 Schnuch A, Szlisha C, Uter W. Allergisches Gesichtsekzem. Auswertungen des IVDK und Literaturübersicht. *Hautarzt* 2009; 60: 13–21.
- 26 Uter W, Geier J, Schnuch A, Arnold R. Konzept einer Informations- und Dokumentationsstelle für Kontaktallergien (IDOK) des Informationsverbundes Dermatologischer Kliniken (IVDK). Version 26.03.2003.
- 27 De Groot AC. Patch testing. Patch test concentrations and vehicles for 4 350 Chemicals. 3d Edition, Acdegroot publishing, HV Wapserveen, 2008.
- 28 Santos R, Goossens A. An update on airborne contact dermatitis: 2001–2006. *Contact Dermatitis* 2007; 57: 353–60.
- 29 Stingl G, Maurer D. IgE-mediated allergen presentation via Fc epsilon RI on antigen-presenting cells. *Int Arch Allergy Immunol* 1997; 113: 24–9.
- 30 Levin C, Warshaw E. Protein contact dermatitis: allergens, pathogenesis, and management. *Dermatitis* 2008; 19: 241–51.
- 31 Darsow U, Laifaoui J, Kerschenlohr K, Wollenberg A, Przybilla B, Wüthrich B, Borelli S Jr, Giusti F, Seidenari S, Drzimalla K, Simon D, Disch R, Borelli S, Devillers AC, Oranje AP, De Raeye L, Hachem JP, Dangoisse C, Blondeel A, Song M, Breuer K, Wulf A, Werfel T, Roul S, Taieb A, Bolhaar S, Bruijnzeel-Koomen C, Brönnimann M, Braathen LR, Didierlaurent A, André C, Ring J. The prevalence of positive reactions in the atopy patch test with aeroallergens and food allergens in subjects with atopic eczema: a European multicenter study. *Allergy* 2004; 59: 1318–25.
- 32 Darsow U, Ring J. Atopie-Patch-Test mit Aeroallergenen und Nahrungsmitteln. *Hautarzt* 2005; 56: 1133–40.
- 33 Dickel H, Kuss O, Schmidt A, Kretz J, Diepgen TL. Importance of irritant contact dermatitis in occupational skin disease. *Am J Clin Dermatol* 2002; 3: 283–9.
- 34 Lonne-Rahm SB, Fischer T, Berg M. Stinging and rosacea. *Acta Derm Venereol* 1999; 79: 460–1.
- 35 Jappe U, Schnuch A, Uter W. Rosacea and contact allergy to cosmetics and topical medicaments – retrospective analysis of multicentre surveillance data 1995–2002. *Contact dermatitis* 2005; 52: 96–101.
- 36 Jappe U, Schäfer T, Schnuch A, Uter W. Contact allergy in patients with rosacea: a clinic-based, prospective epidemiological study. *J Eur Acad Dermatol Venereol* 2008; 22: 1208–14.
- 37 Cook BA, Warshaw EM. Role of topical calcineurin inhibitors in the treatment of seborrheic dermatitis: a review of pathophysiology, safety, and efficacy. *Am J Clin Dermatol* 2009; 10: 103–18.
- 38 Worm M, Sterry W. Perikuläre Kontaktexzeme. *Klin Monatsbl Augenheilkd* 2005; 853–5.
- 39 De Groot AC, van Ginkel CJ, Weijland JW. Statement of ingredients of cosmetics. *Ned Tijdschr Geneesk* 1997; 141:1747–8.
- 40 De Groot AC, Weijland JW. Conversion of common names of cosmetic allergens to the INCI nomenclature. *Contact Dermatitis* 1997; 37: 145–50.
- 41 Werfel T, Aberer W, Augustin M, Biedermann T, Fölster-Holst R, Friedrichs F, Gieler U, Heratizadeh A, Kapp A, Przybilla B, Rietschel E, Schlaeger M, Schmid-Grendelmeier P, Sitter H, Staab D, Szczepanski R, Vieluf D, Voigtman I, Worm M. AWMF-Leitlinie: Neurodermitis. 04/2008. <http://www.uni-duesseldorf.de/AWMF/III/013-027.htm>.
- 42 Hultsch T, Kapp A, Spergel J. Immunomodulation and safety of topical calcineurin inhibitors for the treatment of atopic dermatitis. *Dermatology* 2005; 211: 174–87.
- 43 Callen J, Chamlin S, Eichenfield LF, Ellis C, Girardi M, Goldfarb M, Hanifin J, Lee P, Margolis D, Paller AS, Piacquadio D, Peterson W, Kaulback K, Fennerty M, Wintroub BU. A systematic review of the safety of topical therapies for atopic dermatitis. *Br J Dermatol* 2007; 156: 203–21.
- 44 Ashcroft DM, Chen LC, Garside R, Stein K, Williams HC. Topical pimecrolimus for eczema. *Cochrane Database Syst Rev* 2007; Issue 4. Art. No.: CD005500. DOI: 10.1002/14651858.CD005500.pub2. Publ. online Okt 17, 2007.
- 45 Day I, Lin AN. Use of pimecrolimus cream in disorders other than atopic dermatitis. *J Cutan Med Surg* 2008; 12: 17–26.
- 46 Luger T, Paul C. Potential new indications of topical calcineurin inhibitors. *Dermatology* 2007; 215: 45–54.
- 47 Mensing CO, Mensing CH, Mensing H. Treatment with pimecrolimus cream 1 % clears irritant dermatitis of the periorbital region, face and neck. *Int J Dermatol* 2008; 47: 960–4.
- 48 Jacobi A, Braeutigam M, Mahler V, Schultz E, Hertl M. Pimecrolimus 1 % cream in the treatment of facial psoriasis: a 16-week open-label study. *Dermatology* 2008; 216: 133–6.
- 49 Langley RGB, Luger TA, Cork MJ, Schneider D, Paul C. An Update on the Safety and Tolerability of Pimecrolimus Cream 1 %: Evidence from Clinical Trials and Post-Marketing Surveillance. *Dermatology* 2007; 215 (Suppl 1): 27–44.
- 50 Luger T, Loske KD, Elsner P, Kapp A, Kerscher M, Korting HC, Krutmann J, Niedner R, Röcken M, Ruzicka T, Schwarz T. AWMF-Leitlinie: Topische Dermatotherapie mit Glukokortikoiden – Therapeutischer Index. *J Dtsch Dermatol Ges* 2004; 2: 629–34.